



International Journal of Innovative Technologies in Social Science

e-ISSN: 2544-9435

Operating Publisher
SciFormat Publishing Inc.
ISNI: 0000 0005 1449 8214

2734 17 Avenue SW,
Calgary, Alberta, T3E0A7,
Canada
+15878858911
editorial-office@sciformat.ca

ARTICLE TITLE SLAP II REPAIR - NEW TECHNIQUES, COMPLICATIONS AND CLINICAL OUTCOMES

DOI [https://doi.org/10.31435/ijitss.1\(49\).2026.5679](https://doi.org/10.31435/ijitss.1(49).2026.5679)

RECEIVED 12 January 2026

ACCEPTED 16 March 2026

PUBLISHED 24 March 2026

LICENSE



The article is licensed under a **Creative Commons Attribution 4.0 International License**.

© The author(s) 2026.

This article is published as open access under the Creative Commons Attribution 4.0 International License (CC BY 4.0), allowing the author to retain copyright. The CC BY 4.0 License permits the content to be copied, adapted, displayed, distributed, republished, or reused for any purpose, including adaptation and commercial use, as long as proper attribution is provided.

SLAP II REPAIR - NEW TECHNIQUES, COMPLICATIONS AND CLINICAL OUTCOMES

Michalina Adamczyk (Corresponding Author, Email: madamczyk01@o2.pl)
Municipal Hospital in Siemianowice Śląskie, Siemianowice Śląskie, Poland
ORCID ID: 0009-0002-6325-8298

Aleksandra Lisowska
Municipal Hospital in Siemianowice Śląskie, Siemianowice Śląskie, Poland
ORCID ID: 0009-0008-4917-821X

Pola Sitek
Municipal Hospital in Siemianowice Śląskie, Siemianowice Śląskie, Poland
ORCID ID: 0009-0009-2631-8846

Dariusz Szoltys
Municipal Hospital in Siemianowice Śląskie, Siemianowice Śląskie, Poland
ORCID ID: 0009-0000-2687-3123

Karolina Zygoń-Komendarczyk
Municipal Hospital in Siemianowice Śląskie, Siemianowice Śląskie, Poland
ORCID ID: 0009-0005-9916-0972

Katarzyna Oberska
Municipal Hospital in Siemianowice Śląskie, Siemianowice Śląskie, Poland
ORCID ID: 0009-0004-6701-7584

Sandra Olewińska
Municipal Hospital in Siemianowice Śląskie, Siemianowice Śląskie, Poland
ORCID ID: 0009-0003-7018-8440

Tola Kotkiewicz
Municipal Hospital in Siemianowice Śląskie, Siemianowice Śląskie, Poland
ORCID ID: 0009-0001-6578-3910

Hanna Grygorcewicz
University Clinical Hospital No. 2 of the Pomeranian Medical University in Szczecin, Szczecin, Poland
ORCID ID: 0009-0009-1260-8308

Yelyzaveta Petrenko
Municipal Hospital Complex in Chorzów, Chorzów, Poland
ORCID ID: 0009-0005-9481-472X

ABSTRACT

Superior labrum anterior to posterior (SLAP) type II lesions represent a clinically significant source of shoulder pain and dysfunction, particularly in young athletes and individuals engaged in repetitive overhead activities. Detachment of the superior labrum and biceps anchor disrupts glenohumeral biomechanics, potentially leading to instability, mechanical symptoms and impaired athletic performance. Although arthroscopic repair remains the standard surgical approach, optimal management strategies continue to evolve in response to variable return-to-sport rates and procedure-related complications observed with traditional techniques.

Contemporary surgical concepts emphasize anatomic restoration of the labral-biceps complex while minimizing implant-related morbidity. Innovations such as anatomic double-pulley constructs aim to distribute fixation forces more evenly and reduce peel-back stress during overhead motion. Knotless anchor systems and low-profile suture-tape constructs have been developed to eliminate intra-articular knots, decrease chondral irritation and facilitate smoother rehabilitation. In parallel, single-portal approaches seek to reduce soft-tissue disruption without compromising biomechanical stability. For selected patients particularly those with degenerative labral tissue or advanced age, biceps-based alternatives such as tenodesis provide a viable strategy with comparable functional outcomes and potentially earlier pain relief.

Early and mid-term results of these contemporary techniques demonstrate meaningful improvements in pain, shoulder function and patient satisfaction. Nevertheless, postoperative stiffness, persistent discomfort and incomplete return to high-demand activity remain clinically relevant challenges. Careful patient selection, meticulous surgical execution and individualized rehabilitation protocols are essential for optimizing outcomes. Further long-term, high-quality studies are required to refine treatment algorithms and establish durable, evidence-based recommendations.

KEYWORDS

SLAP II Lesion, Arthroscopic Repair, Knotless Anchor, Double-Pulley Repair, Biceps Tenodesis, Clinical Outcomes

CITATION

Michalina Adamczyk, Aleksandra Lisowska, Pola Sitek, Dariusz Szołtys, Karolina Zygoń-Komendarczyk, Katarzyna Oberska, Sandra Olewińska, Tola Kotkiewicz, Hanna Grygorcewicz, Yelyzaveta Petrenko. (2026) Slap II Repair - New Techniques, Complications and Clinical Outcomes. *International Journal of Innovative Technologies in Social Science*. 1(49). doi: 10.31435/ijitss.1(49).2026.5679

COPYRIGHT

© **The author(s) 2026**. This article is published as open access under the **Creative Commons Attribution 4.0 International License (CC BY 4.0)**, allowing the author to retain copyright. The CC BY 4.0 License permits the content to be copied, adapted, displayed, distributed, republished, or reused for any purpose, including adaptation and commercial use, as long as proper attribution is provided.

Introduction

Shoulder pain remains one of the most frequent musculoskeletal complaints encountered in orthopaedic practice, accounting for a substantial proportion of sports-related and occupational injuries (Luime et al., 2004; Mitchell et al., 2005). Among the various etiologies, superior labrum anterior to posterior (SLAP) lesions represent a distinct and clinically challenging subset. These injuries involve the superior glenoid labrum and the attachment of the long head of the biceps tendon, structures that play a critical role in maintaining glenohumeral stability, force transmission and coordinated shoulder kinematics.

Originally classified by Snyder et al. in 1990 SLAP lesions comprise several subtypes, of which type II - characterized by detachment of the superior labrum and biceps anchor from the glenoid rim - is the most prevalent and clinically significant (Snyder et al., 1990). Disruption of the biceps-labral complex may compromise the concavity - compression mechanism of the glenohumeral joint, contribute to symptomatic instability and impair overhead performance.

Type II lesions are particularly common in overhead athletes, including throwers and swimmers, as well as in manual laborers exposed to repetitive loading. Pathomechanisms include cumulative microtrauma during late cocking and deceleration phases of throwing, where torsional “peel-back” forces act on the biceps anchor, as well as acute traction or compressive injuries such as falls onto an outstretched arm (Andrews et al., 1985; Burkhart & Morgan, 1998; Morgan et al., 1998).

Although arthroscopic repair has traditionally been regarded as the standard of care in young and active patients, clinical outcomes remain heterogeneous. Reported rates of persistent pain, postoperative stiffness and incomplete return to sport have prompted ongoing refinement of surgical strategies. Contemporary techniques

- including knotless fixation systems, anatomic double-pulley constructs, single-portal approaches and biceps-based alternatives - reflect an effort to optimize biomechanical restoration while reducing implant-related morbidity (Chia & Hatrick, 2015; Z. Liu et al., 2024; Mostello et al., 2020; Parnes et al., 2015; Song et al., 2022).

Given the evolving surgical landscape and the continued debate regarding optimal management, a comprehensive synthesis of current techniques and outcomes is warranted. The objective of this review is to critically analyze contemporary surgical approaches for SLAP II repair with emphasis on biomechanical rationale, clinical outcomes and procedure-related complications, in order to inform evidence-based decision-making in diverse patient populations.

Methods

A narrative review design was adopted to synthesize and critically evaluate contemporary evidence regarding surgical management of type II SLAP lesions. The objective was to provide a focused yet comprehensive overview of modern arthroscopic techniques, associated clinical outcomes and reported complications with particular emphasis on recent technical innovations and evolving surgical concepts.

A structured search strategy was applied using the PubMed database. The database search strategy was constructed using predefined keywords to make comprehensive retrieval of relevant studies, as follows: (“SLAP II lesion”) AND (“SLAP repair” OR “arthroscopic repair”) AND (“biceps anchor” OR “knotless anchor”) AND (“clinical outcomes” OR “complications”). The search was restricted to studies published between 2015 and 2025, with prioritization of literature from the most recent five years to ensure clinical relevance and inclusion of evolving techniques.

Inclusion criteria:

- English-language publications;
- Original clinical studies, including prospective or retrospective cohort analyses, comparative studies, and technical notes presenting clinical data;
- Investigations specifically addressing surgical techniques, fixation constructs, clinical outcomes, or complications related to type II SLAP repair.

Exclusion criteria:

- Non-English publications;
- Review articles without original clinical data;
- Case reports lacking sufficient methodological detail;
- Studies focusing exclusively on non-type II SLAP lesions or unrelated shoulder pathology.

To ensure completeness, reference lists of eligible articles were manually screened to identify additional relevant studies not captured in the primary search. Data extraction was performed qualitatively and focused on surgical technique characteristics, fixation methods, patient demographics, follow-up duration, reported functional outcome measures, complication profiles and rates of return to activity. Given the narrative design, no formal risk-of-bias assessment or meta-analytic pooling was conducted; instead, findings were synthesized descriptively to provide clinically meaningful interpretation and contextual analysis.

Anatomy and Classification

The superior glenoid labrum is a fibrocartilaginous structure that deepens the glenoid fossa, increases the concavity of the glenoid socket and contributes to glenohumeral joint stability by serving as the attachment site for the long head of the biceps tendon and portions of the glenohumeral ligaments. The labrum enhances joint stability by increasing concavity compression and serving as a barrier to humeral head translation, particularly during overhead motions where dynamic and static stabilizers are challenged. The superior aspect of the labrum has a relatively tenuous blood supply compared with other regions, rendering it more susceptible to degenerative changes and injury (Clark & Harryman, 1992; Cuéllar et al., 2017).

SLAP lesions - superior labrum anterior to posterior tears - were first comprehensively described by Snyder and colleagues in 1990 based on arthroscopic findings. The original classification delineated four principal patterns of injury involving the superior labrum and the biceps anchor (Snyder et al., 1990):

Type I lesions are characterized by degenerative fraying of the superior labrum with the biceps anchor remaining intact; these lesions are often incidental findings and may be asymptomatic, especially in middle-aged patients.

Type II lesions demonstrate detachment of both the superior labrum and the biceps anchor from the glenoid, leading to instability of the labral-biceps complex and representing the most clinically significant variant due to its impact on shoulder mechanics and pain generation.

Type III SLAP lesions consist of a bucket-handle tear of the superior labrum with the biceps tendon attachment preserved.

Type IV lesions extend the bucket-handle tear into the substance of the biceps tendon itself, often complicating repair and recovery.

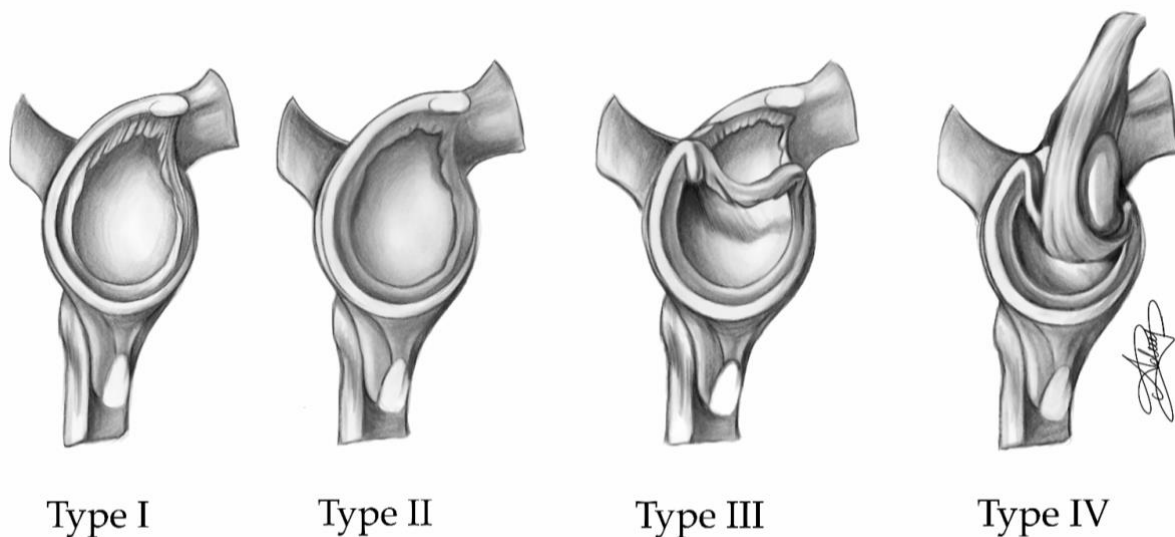


Fig.1. Snyder classification of superior labrum anterior to posterior (SLAP) lesions, illustrating types I–IV.

Subsequent classifications have expanded on Snyder's original nomenclature, identifying additional subtypes of SLAP lesions based on location, extension into surrounding structures and combined instability patterns. For example, Morgan et al. described anterior, posterior, and combined variants of Type II SLAP tears, while Maffet et al. and Powell et al. proposed further extensions of Type II lesions with additional labral involvement (Maffet et al., 1995; Morgan et al., 1998; Powell et al., 2004). Current descriptive systems may include up to ten distinct SLAP types, though Snyder's four-type classification remains the most widely recognized and clinically utilized framework (Maffet et al., 1995; Morgan et al., 1998; Snyder et al., 1990).

Detailed understanding of normal labral anatomy and its variants is essential for accurate diagnosis and surgical planning. Variations such as a sublabral recess, sublabral foramen or a Buford complex can mimic pathological tears on imaging studies and lead to misdiagnosis if not correctly recognized (De Maeseneer et al., 2000; Mercouris & Mercouris, 2023). The anterosuperior labrum, which anchors the long head of the biceps tendon is particularly prone to injury due to its relatively poor vascularity and exposure to torsional and shear forces during overhead activity (Clark & Harryman, 1992; Wilk et al., 2013).

Pathophysiology and Diagnosis

SLAP II lesions typically result from a combination of repetitive overhead activity, acute traumatic events and traction forces applied to the biceps-labral complex. In overhead athletes - such as baseball pitchers, volleyball players and swimmers - the so-called “peel-back” mechanism describes the torsional load placed on the superior labrum when the shoulder is abducted and externally rotated during late cocking and early acceleration phases of throwing leading to gradual detachment of the labrum and biceps anchor (Burkhart & Morgan, 1998). Acute trauma, such as a fall onto an outstretched hand or sudden traction on the arm can generate sufficient force to avulse the labrum from the glenoid in individuals regardless of sport participation (Maffet et al., 1995). Additional pathomechanical factors include internal impingement and posterior shoulder tightness, which may increase shear forces across the superior labrum during dynamic motion (Corpus et al., 2016).

Clinically, patients with SLAP II lesions commonly present with anterior or deep shoulder pain exacerbated by overhead activity, a sense of catching or popping during motion and subjective weakness or decreased performance. Mechanical symptoms may be subtle or nonspecific, complicating the clinical diagnosis. A variety of provocative physical examination maneuvers have been developed to aid in the detection of SLAP pathology. Among these, the O’Brien active compression test and Speed’s test are commonly employed, although their sensitivity and specificity vary widely in isolation. Research indicates that no single test can reliably diagnose SLAP tears and combinations of maneuvers may improve diagnostic confidence but should be interpreted in the context of the overall clinical picture (Dean et al., 2023).

Imaging plays a central role in confirming the diagnosis and ruling out anatomical variants or concomitant shoulder pathology. Magnetic resonance imaging (MRI) and magnetic resonance arthrography (MRA) are widely used as first-line imaging modalities. Recent meta-analyses reveal that MRI demonstrates moderate sensitivity and excellent specificity for detecting SLAP lesions, suggesting it is useful for confirming the presence of pathology but may not be sufficient to rule it out definitively without arthroscopic correlation (Nosratpour et al., 2025). While conventional MRI may suffice in many cases, MRA-particularly with intra-articular contrast - can improve visualization of labral detachments and associated capsulolabral abnormalities (F. Liu et al., 2019). Despite advances in imaging, arthroscopy remains the gold standard for definitive diagnosis offering direct visualization and the ability to assess labral integrity and concomitant shoulder lesions intraoperatively (Nosratpour et al., 2025).

Surgical Techniques for SLAP II Repair

Arthroscopic repair remains the cornerstone of surgical management for type II superior labrum anterior to posterior (SLAP) lesions, particularly in young, active individuals and overhead athletes. The overarching aim of surgical intervention in SLAP II pathology is to re-establish the anatomic attachment of the superior labrum and biceps tendon anchor, thereby restoring normal glenohumeral biomechanics and mitigating the risk of persistent instability and pain. The superior labrum functions as a key stabilizing structure by deepening the glenoid socket, resisting translational forces and serving as the attachment site for the long head of the biceps tendon, which itself contributes to dynamic glenohumeral stability during overhead motion. Disruption of this complex alters force transmission and has been implicated in symptomatic dysfunction, particularly in high-demand overhead activities where torsional and shear forces are maximized during late cocking and follow-through phases of throwing (Burkhart & Morgan, 1998; Cooper et al., 1992).

Historically, arthroscopic SLAP II repair has relied on knotted suture anchor constructs positioned along the superior glenoid rim. These constructs function by approximating the detached labrum and biceps anchor to the glenoid bone, facilitating soft tissue healing and restoring the normal depth of the glenoid concavity. Early clinical series demonstrated improvements in pain and shoulder-specific functional scores with these traditional techniques. However, several limitations have been recognized. Intra-articular knots themselves can become a source of mechanical irritation, rubbing against adjacent cartilage and contributing to chondral abrasion. This is particularly pertinent in smaller glenohumeral joints or in shoulders with limited articular space. Furthermore, the technical demands of secure knot tying and consistent tensioning add complexity to the procedure, increasing operative time and introducing variability between surgeons. Importantly, return-to-sport rates - especially among elite overhead athletes - have been inconsistent, suggesting that mechanical repair alone may not fully address the multifactorial nature of SLAP II pathology (Stetson et al., 2019; Thayaparan et al., 2019).

In response to these challenges, multiple contemporary arthroscopic techniques have been developed, focusing on optimized biomechanical constructs, reduced implant prominence, and facilitation of biological healing. Among these, the anatomic double-pulley repair has drawn significant attention due to its ability to

provide broad and balanced compression across the labral attachment. This technique employs two suture anchors placed horizontally along the superior glenoid rim, interconnected in a manner that distributes fixation forces evenly across the labral margin. By minimizing focal stress and reducing peel-back forces that occur during overhead motion, the double-pulley construct preserves physiologic labral mobility and better approximates the native anatomic footprint of the biceps anchor. Early clinical reports indicate that patients treated with this approach exhibit enhanced labral stability, significant reductions in pain, and favorable improvements in validated functional outcomes, particularly among younger, active cohorts. The success of this method lies in its synthesis of anatomic precision with optimized mechanical load distribution, which may enhance the biological environment for tissue healing and reduce micromotion at the repair site - factors believed to be critical determinants of long-term success (Parnes et al., 2015).

Another significant evolution in SLAP II repair is the adoption of knotless anchor systems. By eliminating intra-articular knots, these constructs aim to reduce implant-related irritation and the potential for cartilage injury. Knotless techniques utilize specialized anchor designs that secure suture constructs without the need for external knot tying within the joint. Simplified knotless mattress configurations have been associated with decreased postoperative discomfort and a more streamlined rehabilitation course, while low-profile suture-tape constructs increase the surface area of labral compression and maintain a smooth articular interface, potentially enhancing early functional outcomes. Clinical studies examining these constructs report generally favorable short-term functional gains, low incidence of knot-related complications, and improved patient comfort, supporting their increasing clinical adoption. From a surgical perspective, knotless systems also offer technical advantages by simplifying suture management and reducing variability associated with knot tying; however, they demand meticulous anchor placement and careful control of labral tensioning, as excessive constraint of the superior labrum can restrict physiologic motion and limit functional recovery (Chia & Hatrick, 2015; Mostello et al., 2020).

Parallel to advancements in fixation constructs, there has also been increasing interest in surgical approaches aimed at reducing soft-tissue trauma and operative morbidity. Single-portal arthroscopic techniques represent one such development, as they limit capsular violation and reduce the number of access portals required during the procedure. By minimizing soft-tissue disruption, these approaches may potentially decrease postoperative pain and facilitate earlier functional recovery.

Single-portal arthroscopic repair is typically performed with the patient in the beach-chair position and requires careful instrument control through a single working portal. Liu et al. reported significant improvements in patient-reported pain and shoulder function following single-portal arthroscopic SLAP II repair without early structural failures, highlighting the potential benefits of reduced surgical morbidity (Z. Liu et al., 2024). Nevertheless, these techniques require advanced arthroscopic skills and careful case selection, as complex or extensive labral tears may not always be amenable to limited portal access.

In contrast to labral preservation strategies, biceps-based alternatives such as arthroscopic modified double-row biceps tenodesis have gained traction for selected patient populations, particularly older individuals or those with degenerative changes of the biceps-labral complex. Tenodesis alters the loading pattern of the long head of the biceps by anchoring the tendon outside the glenohumeral joint, thereby eliminating traction forces on a potentially compromised labrum. Comparative clinical studies suggest that tenodesis may provide earlier pain relief and functional outcomes comparable to labral repair, particularly when labral tissue quality is diminished or in patients at higher risk for repair failure. By shifting the focus from strict anatomic restoration to functional symptom resolution and tendon load redistribution, tenodesis represents a patient-specific alternative that expands the surgical armamentarium (Song et al., 2022).

Collectively, these evolving arthroscopic techniques reflect a paradigm shift in SLAP II management toward precise anatomic reconstruction, minimized implant burden, and individualized surgical planning. Early and mid-term clinical evidence indicates that these methods can provide effective pain relief, improved shoulder function, and reduced incidences of select technical complications when compared with traditional knotted suture repairs. The continued refinement of fixation constructs and procedural strategies underscores the necessity of tailoring surgical interventions to the individual patient's anatomy, activity level, and tissue quality to achieve optimal and durable outcomes across diverse clinical scenarios.

Table 1. Contemporary surgical techniques for SLAP II repair - biomechanical rationale and clinical considerations

Technique	Fixation principle	Biomechanical rationale	Clinical advantages	Limitations/ Risks	Ideal patient profile
Traditional knotted suture anchor repair	Suture anchors with intra-articular knots	Restores labral height and the native biceps anchor footprint, re-establishing concavity-compression and stability during overhead motion	Well-established method with predictable pain relief and satisfactory functional improvement in many active patients	Risk of knot prominence causing irritation or chondral abrasion; technically demanding; variable return-to-sport rates in elite throwers	Young, active patients with good tissue quality and moderate athletic demands
Anatomic double-pulley repair	Two anchors, horizontal compression	Provides uniform load distribution and reduces peel-back forces during abduction-external rotation, potentially enhancing healing	Improved labral compression and stability; favorable mid-term outcomes in high-demand and military populations	Greater technical complexity and operative time; risk of over-constraint if tensioning is excessive	Young overhead athletes and patients exposed to repetitive torsional shoulder stress
Knotless anchor repair (including suture-tape constructs)	Knotless anchor fixation	Reduces hardware prominence and decreases cartilage contact stress; broader compression with suture tape may limit tissue cut-through	Less irritation; improved early postoperative comfort	Potential over-tensioning of the labrum	Active patients with isolated SLAP II lesions seeking reduced postoperative discomfort
Biceps tenodesis (modified double-row or suprapectoral/subpectoral fixation)	Detachment + tendon fixation	Eliminates traction forces on the superior labrum while preserving elbow flexion and supination strength	Earlier pain relief in selected populations; comparable functional outcomes to repair in middle-aged patients	Alters native anatomy; not an anatomic labral restoration; potential cosmetic deformity (rare)	>35–40 yrs / degenerative tissue quality, revision cases, or failed prior SLAP repair

Clinical Outcomes

Clinical outcomes following SLAP II repair are strongly influenced by the surgical technique employed, patient selection and adherence to structured postoperative rehabilitation. Contemporary arthroscopic strategies - including anatomic double-pulley constructs, knotless anchor systems, single-portal approaches, and biceps-based alternatives - have demonstrated generally favorable short- to mid-term outcomes, though heterogeneity in outcome measures, follow-up durations and patient populations remains a limitation in interpreting results.

Anatomic double-pulley repairs aim to reproduce the native labral footprint while distributing fixation forces evenly across the superior glenoid. By minimizing peel-back stress during overhead activity, this technique theoretically reduces micro-instability and enhances labral healing. Parnes et al. reported improved early patient-reported outcomes and restoration of labral stability in young, active individuals, with reductions in pain scores and improved shoulder function compared with historical cohorts undergoing traditional knotted repair (Parnes et al., 2015). These outcomes highlight the biomechanical advantage of horizontal compression and the importance of maintaining physiologic labral mobility to facilitate functional recovery.

Knotless anchor systems, including simplified mattress and low-profile suture-tape constructs provide a comparable biomechanical footprint while eliminating intra-articular knots, reducing hardware-related irritation and chondral abrasion. Early studies demonstrate that patients undergoing knotless repairs achieve significant improvements in functional scores, reduced postoperative discomfort and lower rates of knot-related complications (Chia & Hatrick, 2015; Mostello et al., 2020). The broad labral compression achieved with suture tape has been proposed to optimize healing by maintaining intimate contact between the labrum and glenoid while preserving joint congruity, facilitating smoother rehabilitation and earlier return to activity.

Surgical approaches aimed at reducing procedural morbidity have also been described. Clinical series evaluating single-portal repair have reported meaningful improvements in pain and functional scores. Liu et al. reported a single-portal arthroscopic SLAP repair technique performed in the beach-chair position and demonstrated significant short-term improvements in patient-reported pain and functional outcomes without early repair failures (Z. Liu et al., 2024). By limiting portal-related soft-tissue trauma and simplifying instrument management, this approach may contribute to improved postoperative comfort and rehabilitation. However, successful application requires advanced arthroscopic skill and careful patient selection, particularly in cases involving extensive or complex labral pathology.

Biceps-based alternatives, particularly arthroscopic modified double-row tenodesis, have been investigated as adjuncts or alternatives in patients with degenerative labral tissue or in older populations. Song et al. reported that patients undergoing tenodesis experienced earlier pain relief and higher satisfaction, while achieving functional outcomes comparable to labral repair. (Song et al., 2022). These results underscore the importance of tailoring treatment to tissue quality, age, and activity demands. By offloading the biceps-labral complex, tenodesis may reduce the risk of persistent symptoms when labral healing potential is limited, providing a rationale for selective application in patients at higher risk of repair failure.

Overall, contemporary repair strategies demonstrate encouraging early and mid-term clinical outcomes, with improvements in pain, shoulder function and patient satisfaction. Success is closely tied to precise restoration of labral anatomy, minimization of hardware-related complications and individualized postoperative rehabilitation. Despite these advances, variability in functional outcomes persists, particularly among older patients and high-demand overhead athletes, highlighting the continued need for patient-specific surgical planning and long-term evaluation of evolving techniques.

Table 2. Reported clinical outcomes of contemporary SLAP II surgical techniques

Study	Study Design and Population	Technique	Follow-up	Functional outcomes	Return to sport	Complications
Parnes et al. (2015)	Active military and young physically demanding population; predominantly <35 year	Anatomic double-pulley repair with two horizontal anchors	Minimum 5–6 years	Significant improvement in ASES and Single Assessment Numeric Evaluation (SANE) scores; substantial reduction in pain and restoration of shoulder stability	Approximately 80% of patients returned to full duty and recreational activity; high rates of return in non-elite overhead athletes	Low rate of structural failure; isolated cases of incomplete healing; minimal implant-related irritation reported
Chia & Hatrick (2015)	Prospective technical and clinical evaluation in active patients with isolated SLAP II lesions	Knotless anchor mattress configuration	Short- to mid-term (2–3 years)	Improved shoulder-specific outcome scores; reduction in postoperative discomfort compared with historical knotted controls	Favorable return to pre-injury activity levels in recreational athletes; less data available for elite throwers	Low incidence of knot irritation and chondral abrasion; no significant early anchor-related failures
Mostello et al. (2020)	Cohort study evaluating low-profile suture-tape constructs	Knotless suture-tape fixation providing broad labral compression	Mid-term follow-up	Marked improvement in functional outcome measures and patient-reported satisfaction; early pain relief noted	Encouraging return-to-activity rates; performance-dependent outcomes in overhead athletes	Reduced hardware prominence; minimal reports of mechanical irritation; no increased stiffness compared to traditional repair
Liu et al. (2024)	Clinical series evaluating single-portal arthroscopic repair in beach-chair position	Single-portal, reduced soft-tissue approach with knotless fixation	Short-term	Significant improvement in patient-reported pain scores and shoulder function; rapid early recovery	Early return to daily activities; limited long-term sport-specific data	No early structural failures reported; low postoperative stiffness in early follow-up
Song et al. (2022)	Comparative study: SLAP repair vs modified double-row biceps tenodesis	Arthroscopic labral repair vs double-row tenodesis	Mid-term	Comparable overall functional outcomes between groups; earlier pain relief observed in tenodesis cohort	Similar return-to-activity rates; tenodesis group reported faster symptomatic recovery	Lower persistent pain in tenodesis group in selected patients; repair group demonstrated slightly higher rates of residual anterior shoulder discomfort

Complications and Failures

Despite substantial advances in arthroscopic techniques for SLAP II repair, complications remain a clinically significant concern, affecting both patient satisfaction and functional outcomes. The spectrum of adverse events includes postoperative stiffness, persistent shoulder pain, failure of labral healing, recurrent instability and incomplete return to pre-injury levels of activity. These outcomes are influenced by a combination of technique-related and patient-specific factors, emphasizing the complexity of managing superior labral pathology.

Technique-related complications are most frequently reported with traditional knotted repair constructs. Knot irritation, suture prominence, chondral abrasion, and mechanical impingement within the glenohumeral joint have been documented as sources of postoperative discomfort and may limit early functional recovery. To address these issues, knotless and low-profile fixation systems have been developed. Simplified knotless mattress constructs and suture-tape repairs provide broad labral compression while eliminating intra-articular knots, thereby reducing irritation and minimizing potential cartilage damage. Both Chia & Hatrick and Mostello et al. reported low rates of implant-related complications with these techniques, highlighting their clinical advantage (Chia & Hatrick, 2015; Mostello et al., 2020). However, the benefits of knotless systems are contingent upon precise anchor placement. Over-constraint of the labrum due to non-anatomic tensioning or mispositioned anchors may still lead to stiffness, persistent pain and limitation in range of motion (Parnes et al., 2015).

Single-portal approaches have been proposed as strategies to reduce intra-articular hardware and minimize soft-tissue trauma during arthroscopic SLAP II repair. By limiting the number of implants and portals used during surgery, these techniques aim to decrease implant-related irritation and reduce surgical morbidity while maintaining adequate biomechanical stability of the labral repair. In particular, knotless fixation constructs may allow stable labral reattachment with a lower intra-articular profile, potentially decreasing the risk of cartilage irritation and postoperative discomfort (Chia & Hatrick, 2015; Mostello et al., 2020).

Single-portal arthroscopic techniques represent another evolution toward less invasive procedures. Liu et al. reported that a single-portal repair technique performed in the beach-chair position resulted in significant improvements in patient-reported pain and shoulder function at short-term follow-up, without evidence of early structural failure (Z. Liu et al., 2024). The reduced number of portals may decrease soft-tissue disruption and postoperative pain, potentially facilitating early rehabilitation. Nevertheless, the technical demands of single-portal arthroscopy require precise instrument control and careful anchor placement, particularly in complex or extensive SLAP lesions where visualization and working angles may be more limited.

Patient-specific factors remain critical determinants of complications and repair failure following SLAP II surgery. Increasing age, degenerative changes of the superior labrum and biceps anchor, and high-demand overhead activity have been associated with less predictable outcomes after conventional labral repair. In such cases, persistent postoperative pain may reflect ongoing traction forces transmitted through the long head of the biceps tendon rather than failure of the labral fixation itself.

Consequently, biceps-based procedures have been explored as alternative strategies in selected patient populations. Song et al. demonstrated that arthroscopic modified double-row biceps tenodesis provided reliable pain relief and favorable functional outcomes in patients with SLAP pathology, particularly in those with degenerative labral tissue or increased risk of repair failure (Song et al., 2022). By altering the loading pattern of the biceps-labral complex, tenodesis may reduce residual stress on the superior labrum and thereby decrease the likelihood of persistent symptoms in patients with compromised tissue quality.

While modern techniques - including anatomic double-pulley constructs, knotless systems, minimal-implant repairs and single-portal approaches - have reduced the incidence of technical complications and improved early functional outcomes, persistent pain, stiffness and incomplete return to sport remain relevant. These observations underscore the importance of meticulous surgical technique, individualized selection of repair strategy based on patient anatomy and activity demands, and structured, progressive postoperative rehabilitation. Continued investigation into technique-specific complication profiles and long-term durability will be essential to optimize outcomes and guide evidence-based surgical decision-making for SLAP II lesions.

Table 3. Complications associated with contemporary SLAP II repair techniques

Complication Category	Pathomechanism	Clinical Presentation	Techniques Most Commonly Associated	Reported Trends in Literature	Clinical Implications
Implant-related complications	Prominent intra-articular knots, anchor malposition, suture abrasion against articular cartilage, excessive implant burden	Persistent localized joint pain, mechanical clicking, catching sensation, chondral irritation observed arthroscopically	Primarily traditional knotted suture anchor repairs; less frequently early-generation anchors	Knot irritation and chondral abrasion reported more often with knotted constructs; reduced incidence observed with knotless and low-profile suture-tape systems	May necessitate revision arthroscopy for hardware removal or debridement; emphasizes importance of low-profile constructs and accurate anchor placement
Biological failure (non-healing or re-detachment)	Inadequate biological integration at labrum–glenoid interface, persistent micromotion at repair site, compromised tissue quality, excessive tension at fixation	Recurrent deep shoulder pain, positive provocative tests, MRI evidence of persistent detachment	All repair types; higher risk in degenerative tissue and high-demand athletes; possibly increased in minimal single-anchor constructs in select cases	Non-healing rates generally low but present across techniques; risk influenced more by patient factors than construct type	May require revision repair or conversion to biceps tenodesis; highlights importance of patient selection and biological environment optimization
Functional limitation (postoperative stiffness or over-constraint)	Excessive labral tensioning, overtightening of biceps anchor, capsular scarring, altered glenohumeral kinematics	Restricted external rotation, pain at end range of motion, delayed rehabilitation progress	More frequently described in aggressively tensioned repairs, including double-anchor constructs if improperly balanced	Stiffness reported as one of the most common short-term complications; incidence varies depending on rehabilitation protocol	Requires structured physiotherapy; occasionally manipulation under anesthesia or revision if severe over-constraint persists
Persistent pain without structural failure	Residual biceps tendon pathology, altered load distribution, unrecognized concomitant pathology (rotator cuff, internal impingement)	Ongoing anterior or superior shoulder pain despite intact repair on imaging	Observed after both labral repair and tenodesis; higher incidence in older patients with degenerative changes	Studies suggest that pain may be related to underlying biceps degeneration rather than mechanical repair failure	Supports individualized decision-making; may justify tenodesis in selected populations

Return to sport	Incomplete restoration of dynamic shoulder stability, altered proprioception, psychological factors, sport-specific biomechanical demands	Inability to return to pre-injury performance level despite pain reduction	Reported across all repair techniques; particularly relevant in elite overhead athletes	Return-to-sport rates variable (often 60–85% in overhead athletes); lower in elite throwing populations	Emphasizes need for sport-specific rehabilitation and careful preoperative counseling regarding realistic expectations
Revision surgery	Combination of structural failure, persistent pain, stiffness, or implant-related irritation	Recurrence of symptoms requiring operative reassessment	Historically more common after traditional repairs; may occur after any technique depending on patient factors	Revision rates generally low but clinically relevant; conversion to biceps tenodesis common salvage strategy	Demonstrates that technique selection should consider age, tissue quality, and activity level

Discussion

The surgical management of type II SLAP lesions has undergone significant evolution over the past decade, driven by advances in arthroscopic instrumentation, improved understanding of labral-biceps biomechanics and the persistent challenges associated with traditional knotted repairs. While conventional techniques have reliably restored labral attachment they are often associated with knot-related irritation, chondral abrasion and variable return-to-sport rates, particularly among overhead athletes who place high functional demands on the superior labrum and biceps anchor (Erickson et al., 2016). These limitations have motivated the development of new arthroscopic strategies designed to optimize both biomechanical restoration and clinical outcomes.

Among contemporary innovations, the anatomic double-pulley repair has emerged as a biomechanically rational approach, aiming to replicate the native footprint of the superior labrum and biceps anchor while distributing fixation forces to minimize peel-back stress. Early clinical observations suggest that this technique provides enhanced labral stability, improved pain relief, and satisfactory functional outcomes in young, active patients (Parnes et al., 2015). Despite these promising early results, long-term follow-up remains limited, and additional data are required to determine the durability of repair under high-demand conditions.

Knotless anchor systems represent another significant advancement with both simplified mattress and low-profile suture-tape constructs demonstrating favorable early functional outcomes and reduced incidence of intra-articular irritation (Chia & Hatrick, 2015; Mostello et al., 2020). By eliminating knots within the joint, these techniques decrease the risk of chondral injury and facilitate smoother postoperative rehabilitation. Early reports indicate that knotless fixation may reduce intra-articular irritation and support improved early functional recovery. However, proper anchor placement and avoidance of over-constraint remain critical as excessive tension may compromise joint mobility and long-term outcomes.

Single-portal approaches provide further refinements by reducing implant burden and minimizing soft-tissue disruption. Techniques that limit the number of implants or arthroscopic portals are intended to reduce intra-articular hardware prominence and decrease surgical morbidity while maintaining adequate labral fixation. Single-portal arthroscopic repair techniques have demonstrated encouraging early results, with significant improvements in pain and shoulder function reported during short-term follow-up (Z. Liu et al., 2024). Nevertheless, these procedures require advanced arthroscopic skills, and the limited availability of long-term outcome data restricts conclusions regarding their durability and reproducibility across broader patient populations.

Biceps-based alternatives, particularly modified double-row tenodesis have gained relevance for selected patient subgroups, including older individuals or those with degenerative biceps-labral complexes. Comparative studies indicate that tenodesis provides earlier pain relief while maintaining functional outcomes comparable to labral repair (Song et al., 2022). These findings underscore the necessity of individualized treatment planning with patient age, tissue quality and activity level guiding the choice of repair technique.

Despite these technical advances, complications remain a clinically significant concern. Persistent postoperative pain, stiffness and incomplete return to pre-injury activity are reported even with modern techniques (Chia & Hatrick, 2015; Mostello et al., 2020). Complications often arise from technical factors such as non-anatomic anchor placement, over-constraint, or excessive labral tension (Parnes et al., 2015), as well as patient-specific determinants including tissue quality, age-related degenerative changes and high-demand overhead activity (Song et al., 2022). Recognizing these variables is essential for optimizing outcomes and minimizing repair failure.

The current evidence base, while supportive of evolving techniques, is limited by heterogeneity in study design, follow-up duration, outcome measures and patient demographics. Direct comparative studies evaluating long-term efficacy, biomechanical durability and complication rates of different repair strategies are scarce. Future research should prioritize prospective, multicenter trials with standardized functional outcomes, comprehensive reporting of complications and extended follow-up. Furthermore, biomechanical studies correlating specific construct designs with clinical performance could refine patient-specific decision-making, ultimately enabling more predictable outcomes in diverse populations.

In conclusion, contemporary approaches to SLAP II repair demonstrate a clear trend toward anatomical restoration, reduced implant burden and individualized treatment strategies. Current evidence suggests favorable short-term functional improvement; however, durability across different patient populations remains uncertain. Sustained long-term evaluation will be necessary to establish evidence-based guidelines and optimize management strategies for this complex and functionally significant shoulder pathology.

Limitations

This narrative review has several inherent limitations. The literature search was restricted to PubMed and English-language publications, potentially excluding relevant studies indexed elsewhere or in other languages. The included studies exhibit considerable heterogeneity in surgical techniques, patient demographics, follow-up duration and outcome assessment, limiting the ability to draw direct comparisons or perform quantitative synthesis. While prioritizing recent publications enhances clinical relevance and focuses on evolving techniques, older foundational studies may provide insights into long-term outcomes and complications not captured here. Additionally, the narrative review format precludes formal risk-of-bias assessment or meta-analysis. Many of the contemporary repair techniques, including knotless, double-pulley, single-portal and modified tenodesis procedures, lack extensive long-term follow-up, which restricts definitive conclusions regarding durability, late complications and comparative efficacy across diverse patient populations.

Conclusions

The management of type II SLAP lesions has undergone substantial evolution over the past decade driven by the need to optimize anatomic restoration, minimize complications and improve functional outcomes in a population that frequently includes young, active and overhead athletes. Traditional knotted suture anchor repairs, while effective in many cases are limited by knot-related irritation, chondral abrasion and technical complexity, highlighting the necessity for alternative approaches.

Contemporary surgical strategies - including anatomic double-pulley repairs, knotless anchor systems, and minimally invasive arthroscopic approaches - have demonstrated encouraging early- and mid-term clinical outcomes. These techniques aim to improve fixation stability while reducing implant-related irritation and preserving physiologic labral mobility. Early reports suggest improvements in pain relief, functional recovery, and patient satisfaction following anatomic and knotless repair constructs (Chia & Hatrick, 2015; Mostello et al., 2020; Parnes et al., 2015). In addition, less invasive approaches such as single-portal arthroscopy may reduce soft-tissue disruption and surgical morbidity while maintaining satisfactory early functional outcomes (Z. Liu et al., 2024).

Biceps-based procedures have also emerged as an important alternative for selected patient populations, particularly individuals with degenerative labral-biceps complexes or advanced age. In such cases, biceps tenodesis may provide reliable pain relief and functional outcomes comparable to those achieved with traditional SLAP repair (Song et al., 2022). These findings highlight the importance of individualized surgical decision-making based on patient characteristics, tissue quality, and functional demands.

Despite these advancements, complications remain clinically relevant. Postoperative stiffness, persistent pain and occasional failure of labral healing continue to occur and are influenced by patient-specific factors such as age, tissue quality, activity level and adherence to rehabilitation protocols. Careful patient selection,

meticulous surgical technique and individualized postoperative management are therefore essential to achieving optimal outcomes.

While early evidence supports the biomechanical and clinical advantages of evolving techniques, long-term comparative data remain limited. Future research should focus on prospective, multicenter studies with standardized outcome measures and extended follow-up to determine the durability of these approaches, refine patient selection criteria and establish evidence-based guidelines for the surgical management of type II SLAP lesions.

In summary, modern arthroscopic strategies for SLAP II repair provide a spectrum of options that allow surgeons to tailor interventions to individual patient characteristics, balancing anatomic restoration with minimal invasiveness and optimizing both functional recovery and complication risk. These developments represent an important step toward more individualized surgical management of SLAP II lesions.

Author Contributions

Conceptualization: Michalina Adamczyk, Aleksandra Lisowska.

Literature review and data analysis: Michalina Adamczyk, Pola Sitek, Karolina Zygoń-Komendarczyk.

Manuscript preparation and drafting: Michalina Adamczyk, Aleksandra Lisowska, Tola Kotkiewicz.

Critical revision of the manuscript for important intellectual content: Dariusz Szołtys, Hanna Grygorcewicz, Yelyzaveta Petrenko, Katarzyna Oberska, Sandra Olewińska.

Supervision: Dariusz Szołtys.

All authors contributed to the interpretation of the literature, reviewed the manuscript critically, and approved the final version of the manuscript.

Conflict of Interest: The authors declare that there are no conflicts of interest regarding the publication of this article.

Funding: This research received no external funding.

Ethical Approval: This study is a narrative review of previously published literature and did not involve human participants or animal subjects. Therefore, ethical approval was not required.

REFERENCES

1. Andrews, J. R., Carson, W. G., & McLeod, W. D. (1985). Glenoid labrum tears related to the long head of the biceps. *The American Journal of Sports Medicine*, 13(5), 337–341. <https://doi.org/10.1177/036354658501300508>
2. Burkhart, S., & Morgan, C. (1998). The peel-back mechanism: Its role in producing and extending posterior type II SLAP lesions and its effect on SLAP repair rehabilitation. *Arthroscopy: The Journal of Arthroscopic & Related Surgery*, 14(6), 637–640. [https://doi.org/10.1016/S0749-8063\(98\)70065-9](https://doi.org/10.1016/S0749-8063(98)70065-9)
3. Chia, M. R., & Hatrick, C. (2015). Simplified knotless mattress repair of type II SLAP lesions. *Arthroscopy Techniques*, 4(6), e763–e767. <https://doi.org/10.1016/j.eats.2015.07.024>
4. Clark, J. M., & Harryman, D. T. (1992). Tendons, ligaments, and capsule of the rotator cuff: Gross and microscopic anatomy. *The Journal of Bone and Joint Surgery. American Volume*, 74(5), 713–725.
5. Cooper, D. E., Arnoczky, S. P., O'Brien, S. J., Warren, R. F., DiCarlo, E., & Allen, A. A. (1992). Anatomy, histology, and vascularity of the glenoid labrum: An anatomical study. *The Journal of Bone and Joint Surgery. American Volume*, 74(1), 46–52.
6. Corpus, K. T., Camp, C. L., Dines, D. M., Altchek, D. W., & Dines, J. S. (2016). Evaluation and treatment of internal impingement of the shoulder in overhead athletes. *World Journal of Orthopedics*, 7(12), 776–784. <https://doi.org/10.5312/wjo.v7.i12.776>
7. Cuéllar, R., Ruiz-Ibán, M. A., & Cuéllar, A. (2017). Anatomy and biomechanics of the unstable shoulder. *The Open Orthopaedics Journal*, 11, 919–933. <https://doi.org/10.2174/1874325001711010919>
8. De Maeseneer, M., Van Roy, F., Lenchik, L., Shahabpour, M., Jacobson, J., Ryu, K. N., Handelberg, F., & Osteaux, M. (2000). CT and MR arthrography of the normal and pathologic anterosuperior labrum and labral-bicipital complex. *RadioGraphics*, 20(suppl_1), S67–S81. https://doi.org/10.1148/radiographics.20.suppl_1.g00oc03s67
9. Dean, R. S., Onsen, L., Lima, J., & Hutchinson, M. R. (2023). Physical examination maneuvers for SLAP lesions: A systematic review and meta-analysis of individual and combinations of maneuvers. *The American Journal of Sports Medicine*, 51(11), 3042–3052. <https://doi.org/10.1177/03635465221100977>
10. Erickson, B. J., Jain, A., Abrams, G. D., Nicholson, G. P., Cole, B. J., Romeo, A. A., & Verma, N. N. (2016). SLAP lesions: Trends in treatment. *Arthroscopy: The Journal of Arthroscopic & Related Surgery*, 32(6), 976–981. <https://doi.org/10.1016/j.arthro.2015.11.044>

11. Liu, F., Cheng, X., Dong, J., Zhou, D., Sun, Q., Bai, X., & Wang, D. (2019). Imaging modality for measuring the presence and extent of the labral lesions of the shoulder: A systematic review and meta-analysis. *BMC Musculoskeletal Disorders*, 20(1), 487. <https://doi.org/10.1186/s12891-019-2876-6>
12. Liu, Z., Wang, Y., Liu, P., Chen, W., & Du, C. (2024). A single-portal arthroscopic technique for type II SLAP lesions in the beach chair position. *Arthroscopy Techniques*, 13(2), 102859. <https://doi.org/10.1016/j.eats.2023.10.002>
13. Luime, J., Koes, B., Hendriksen, I., Burdorf, A., Verhagen, A., Miedema, H., & Verhaar, J. (2004). Prevalence and incidence of shoulder pain in the general population: A systematic review. *Scandinavian Journal of Rheumatology*, 33(2), 73–81. <https://doi.org/10.1080/03009740310004667>
14. Maffet, M. W., Gartsman, G. M., & Moseley, B. (1995). Superior labrum-biceps tendon complex lesions of the shoulder. *The American Journal of Sports Medicine*, 23(1), 93–98. <https://doi.org/10.1177/036354659502300116>
15. Mercouris, P., & Mercouris, M. (2023). Superior labrum anterior to posterior lesions: Part 1—Imaging and anatomy with arthroscopic classification. *SA Journal of Radiology*, 27(1), 2706. <https://doi.org/10.4102/sajr.v27i1.2706>
16. Mitchell, C., Adebajo, A., Hay, E., & Carr, A. (2005). Shoulder pain: Diagnosis and management in primary care. *BMJ*, 331(7525), 1124–1128. <https://doi.org/10.1136/bmj.331.7525.1124>
17. Morgan, C., Burkhart, S., Palmeri, M., & Gillespie, M. (1998). Type II SLAP lesions: Three subtypes and their relationships to superior instability and rotator cuff tears. *Arthroscopy: The Journal of Arthroscopic & Related Surgery*, 14(6), 553–565. [https://doi.org/10.1016/S0749-8063\(98\)70049-0](https://doi.org/10.1016/S0749-8063(98)70049-0)
18. Mostello, A. J., Caldwell, P. E., & Pearson, S. E. (2020). Arthroscopic low-profile knotless repair of SLAP tears with suture tape. *Arthroscopy Techniques*, 9(10), e1505–e1509. <https://doi.org/10.1016/j.eats.2020.06.010>
19. Nosratpour, M., Zarei, H., Zaker Moshfegh, M., Mahdavi, M., Moteshakereh, S. M., Shirvani, P., Azizi, M., Parvandi, A., Kazemi, S. M., Sobhani, A., Farrokhi, M., & Amiri, S. (2025). Diagnostic accuracy of magnetic resonance imaging for detecting superior labrum anterior to posterior lesions: A systematic review and meta-analysis. *JSES International*, 9(6), 1972–1987. <https://doi.org/10.1016/j.jseint.2025.05.023>
20. Parnes, N., Ciani, M., Carr, B., & Carey, P. (2015). The double-pulley anatomic technique for type II SLAP lesion repair. *Arthroscopy Techniques*, 4(5), e545–e550. <https://doi.org/10.1016/j.eats.2015.05.009>
21. Powell, S. E., Nord, K. D., & Ryu, R. K. N. (2004). The diagnosis, classification, and treatment of SLAP lesions. *Operative Techniques in Sports Medicine*, 12(2), 99–110. <https://doi.org/10.1053/j.otsm.2004.07.001>
22. Snyder, S. J., Karzel, R. P., Pizzo, W. D., Ferkel, R. D., & Friedman, M. J. (1990). SLAP lesions of the shoulder. *Arthroscopy: The Journal of Arthroscopic & Related Surgery*, 6(4), 274–279. [https://doi.org/10.1016/0749-8063\(90\)90056-J](https://doi.org/10.1016/0749-8063(90)90056-J)
23. Song, Y., Wu, Z., Wang, M., Liu, S., Cong, R., & Tao, K. (2022). Arthroscopic modified double-row biceps tenodesis versus labral repair for the treatment of isolated type II SLAP lesions in non-overhead athletes. *Orthopaedic Surgery*, 14(7), 1340–1349. <https://doi.org/10.1111/os.13229>
24. Stetson, W. B., Polinsky, S., Morgan, S. A., Strawbridge, J., & Carcione, J. (2019). Arthroscopic repair of type II SLAP lesions in overhead athletes. *Arthroscopy Techniques*, 8(7), e781–e792. <https://doi.org/10.1016/j.eats.2019.03.013>
25. Thayaparan, A., Yu, J., Horner, N. S., Leroux, T., Alolabi, B., & Khan, M. (2019). Return to sport after arthroscopic superior labral anterior-posterior repair: A systematic review. *Sports Health*, 11(6), 520–527. <https://doi.org/10.1177/1941738119873892>
26. Wilk, K. E., Macrina, L. C., Cain, E. L., Dugas, J. R., & Andrews, J. R. (2013). The recognition and treatment of superior labral (SLAP) lesions in the overhead athlete. *International Journal of Sports Physical Therapy*, 8(5), 579–600.